

Bicornuate Uterus with Obstructed Hemivagina

J. V. Clark, M.D., and J. S. ...

Department of Obstetrics and Gynecology, The University of Michigan Medical Center, Ann Arbor, Michigan

Abstract: A bicornuate uterus with an obstructed hemivagina was treated by hysterectomy.

The patient presented with a mass in the right lower quadrant. The mass was found to be a bicornuate uterus with an obstructed hemivagina. The patient was treated with hysterectomy and oophorectomy. The patient is doing well postoperatively.

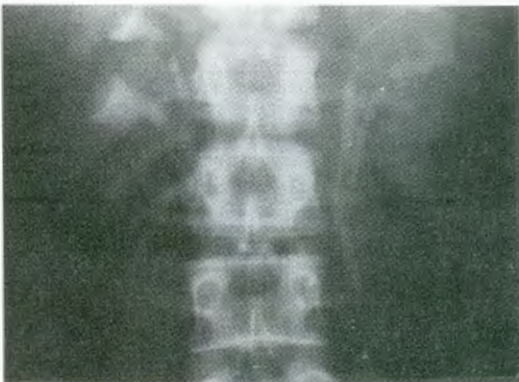


Fig 1



Fig 2

The patient had a mass in the right lower quadrant. The mass was found to be a bicornuate uterus with an obstructed hemivagina.

The patient had a mass in the right lower quadrant. The mass was found to be a bicornuate uterus with an obstructed hemivagina.

The patient had a mass in the right lower quadrant. The mass was found to be a bicornuate uterus with an obstructed hemivagina.

The patient had a mass in the right lower quadrant. The mass was found to be a bicornuate uterus with an obstructed hemivagina.

The patient had a mass in the right lower quadrant. The mass was found to be a bicornuate uterus with an obstructed hemivagina.

Reprint requests: J. V. Clark, M.D., Department of Obstetrics and Gynecology, The University of Michigan Medical Center, Ann Arbor, Michigan.